

## Review Article

## Using Ventrogluteal Site in Intramuscular Injections is a Priority or an Alternative?

**Dilek Kara, MSc, Instructor**

Uludag University School of Health, Department of Nursing, Bursa, Turkey

**Derya Uzelli, MSc, Instructor**

Izmir Katip Çelebi University Faculty of Health Sciences, Department of Nursing, Izmir, Turkey

**Dilek Karaman, MSc, Instructor**

Bülent Ecevit University Ahmet Erdoğın Health Services Vocational School, Department of Health Care Services, Aged Care Program, Kozlu, Zonguldak, Turkey

**Correspondence:** Dilek Kara, Uludag University School of Health, Department of Nursing, 16059 Görükle/Bursa, Turkey. e-mail: dilekkara15@hotmail.com

### Abstract

One of the most commonly used treatment modality in injection applications is intramuscular injection application. Despite it considered as a simple technique, when intramuscular injection process is not done carefully, it can cause serious complications. The injection site that used for intramuscular injection is one of the most important determinants of complications. As well as selection of site for intramuscular injection depends on many factors, it is reported that clinical practitioners often prefer dorsogluteal site. With studies in recent years, it is recommended to use of ventrogluteal site instead of dorsogluteal site for injection because of it is away from the sciatic nerve and large blood vessels, it is more easy to identify and for reasons such as the subcutaneous tissue is being more thinner for intramuscular injection. However, despite the ventrogluteal site is identified as the safest area in intramuscular injection practices, it appears that the health professionals working in different countries often use dorsogluteal site. For this reason, it is needed to make this compilation study for discuss the advantages of use of ventrogluteal site towards dorsogluteal site in intramuscular injection applications, detection of reliable injection site, the disadvantages and reasons of practitioners' use of dorsogluteal site. This compilation study was conducted in order to contribute to make the health professionals, particularly nurses, apply safe intramuscular injections with evaluating the effectiveness of ventrogluteal site usage that seen as an alternative site and the disadvantages of dorsogluteal site with the results of studies and literature reviews.

**Key words:** Intramuscular injection, Injection site, Dorsogluteal site, Ventrogluteal site.

### Introduction

Today, injection applications are the most commonly used forms of pharmacological treatment (Chung et al., 2002, Tuğrul and Denat, 2014). One of the most commonly used treatment modality in injection applications is intramuscular injection application (Kilic et al., 2014, Tuğrul and Denat, 2014). In intramuscular injections, the drug is introduced into the muscle tissue. Because of the muscle tissue is rich in terms of the vein deposits, absorption of drugs delivered via intramuscular injection is faster than subcutaneous application and it can be given that intense drugs which have high irritant effect into the deep muscle tissue (Berman et al., 2008, Hunter,

2008). Despite it considered as a simple technique, when intramuscular injection process is not done carefully, it can cause serious complications. These complications can be listed as abscess, necrosis, hematoma, ecchymosis, infection, pain, periostitis, vascular and nerve injury (Gülınar and Çalıřkan, 2014, Hogston and Simpson, 2002, Kaya et al., 2015, Nicoll and Hesby, 2002, Small, 2004). In the literature, it is stated that, in case of health professionals have the necessary knowledge and skills about intramuscular injections, these complications can be prevent or reduced (Chan et al., 2006, Cocaman and Murray, 2008, Pandian et al., 2006; Stinger et al., 2010).

The injection site that used for intramuscular injection is one of the most important determinants of complications (Nicoll and Hesby, 2002, Gülnar and Çalışkan, 2014). In the literature; it is emphasized that it is important to choose a safe area away from the large blood vessels, nerve and bone structures in intramuscular injection practices (Cocoman and Murray, 2010, Kozier and Berman, 2008, Ramont and Niedringhaus, 2004). The areas used for intramuscular injection practices are reported as; dorsogluteal site, ventrogluteal site, deltoid muscle, vastus lateralis muscle and the rectus femoris muscle (Gülnar and Çalışkan, 2014, Hunter, 2008, Kilic et al., 2014, Soanes, 2000).

As well as selection of site for intramuscular injection depends on many factors, it is reported that clinical practitioners often prefer dorsogluteal site. Considering the work on the subject done by Engstrom et al (2000); it has been found that majority of nurses prefer the dorsogluteal site in injection practices. In their study, Floyd and Meyer (2007) stated that 99% of nurses use dorsogluteal muscle, 9% of nurses use ventrogluteal site for the purpose of intramuscular injection. In Walsh and Brophy's study (2011), they stated that 71% of the nurses prefer to dorsogluteal site for intramuscular injection. In the studies which are handled in Turkey, it has been reported that the majority of nurses prefer to dorsogluteal site during injection applications (Gülnar and Çalışkan, 2014, Güneş et al., 2008, Tuğrul and Denat, 2014).

In a study carried out by Cocoman and Murray (2008); it is stated that health professionals should have more current information about the injection sites. With studies in recent years, it is recommended to use of ventrogluteal site instead of dorsogluteal site for injection because of it is away from the sciatic nerve and large blood vessels, it is more easy to identify and for reasons such as the subcutaneous tissue is being more thinner for intramuscular injection (Carter and McCoy, 2008, Cocoman and Murray, 2008, Malkin, 2008, Walsh and Brophy, 2011). However, despite the ventrogluteal site is identified as the safest area in intramuscular injection practices, it appears that the nurses working in different countries often use dorsogluteal site. For this reason, it is needed to make this compilation study for discuss the advantages of use of ventrogluteal site towards dorsogluteal site in intramuscular injection applications, detection of reliable injection site, the disadvantages and reasons of practitioners' use of dorsogluteal site.

## Objective

This compilation study was conducted in order to contribute to make the health professionals, particularly nurses, apply safe intramuscular injections with evaluating the effectiveness of ventrogluteal site usage that seen as an alternative site and the disadvantages of dorsogluteal site with the results of studies and literature reviews.

## Disadvantages of Using Dorsogluteal Site

Dorsogluteal site that often preferred in intramuscular injection practices consists of the gluteus maximus muscle (Güneş et al., 2008). Despite its usage by health care professionals traditionally, in the literature it is stated that dorsogluteal site is most risky site for injection because of it is rich in terms of vein number, it is close to the sciatic nerve and its subcutaneous tissue is thicker than other sites (Newton et al., 1992; Nicoll and Hesby 2002, Roger and King 2000, Workman, 1999, Wynaden et al., 2006).

In literature, it is stated that the most important complication which may develop after injection of dorsogluteal site is sciatic nerve injury (Beyea and Nicoll 1995, Greenway, 2014, Small, 2004; Yavuz and Karabacak, 2011). Injection practices in this site is not recommended because of the coincide of needle with the sciatic nerve could cause pain, temporary or permanent paralysis in lower legs and feet (Malkin, 2008, Nicoll and Hesby, 2002, Ramtahal et al., 2006). Craven and Hirnle (2009) in their study, they stated that this site should not be used for the purpose of intramuscular injection because of the dorsogluteal site is close to sciatic nerve and superior gluteal artery, injection could be accidentally implemented to subcutaneous tissue.

Taylor et al. (2008) also stated that the dorsogluteal site is a site used for intramuscular injection; the adipose tissue in this site is thick and the injection is often applied to the subcutaneous adipose tissue instead of the muscle tissue. Beyea and Nicholl (1995) reported that dorsogluteal site is most risky site for intramuscular injection due to it is rich in terms of blood vessels and its subcutaneous tissue is thicker than the other sites. Small (2004) in his study, he stated that in intramuscular injections made to the dorsogluteal site, it is common that accidentally drug injection to subcutaneous tissue and inadequate drug absorption, tissue irritation and pain occur more frequently. In the study carried by Nispert (2006), it has inspected that the deep adipose tissue and it has found that 72% of needles applied to the subcutaneous tissue used in dorsogluteal site. Chan et

al. (2006) in a study conducted in a similar manner; they found in injection applications that made to dorsogluteal area includes just 32% of intramuscular injection, 68% of it is applied to the subcutaneous tissue. The study carried out by Elizabeth and Winslow (1996) stated that the injections in dorsogluteal site has been injected (95% of women and 85% of men) into the adipose tissue. In another study, the injections in dorsogluteal site were made specifically for the mildly obese and obese individuals were made adipose tissue and as a result of this, these individuals get low drug absorption rates and it is reported the tissue irritation occurs more frequently (Zaybak et al., 2007).

### **The Studies Reviewed The Efficacy of Using Ventrogluteal Site**

In the literature; using ventrogluteal site in intramuscular injection applications has many advantages and therefore it should be defined as the first intramuscular injection site are reported (DeLaune and Ladner, 2002, Kilic et al., 2014, Yavuz and Karabacak, 2011). However, despite it has being reported as such in literature, it is stated that most of the health professionals are not aware of the advantages of the using ventrogluteal site in intramuscular injection practices (Donaldson and Green, 2005, Greenway, 2004, Kilic et al., 2014).

Ventrogluteal site, firstly used in the beginning of 1950's by Hochstetter as an intramuscular injection site (Greenway, 2014). This site that refers anterolateral (side hip), is composed of gluteus medius and the gluteus minimus muscle (Nicoll and Hesby, 2002, Rodger and King, 2000). In this site, the thickness of subcutaneous tissue is less than other injection sites (Hemsworth, 2000, Hunter, 2008) and in this site, nerves and blood vessels are relatively less. Furthermore, in this site, the muscles are large and well established. For the injection, it is easy to find the limit points. Due to its larger ventrogluteal of muscle mass, in terms of complications, injections done in this area are reported to be more reliable (Güneş et al., 2008).

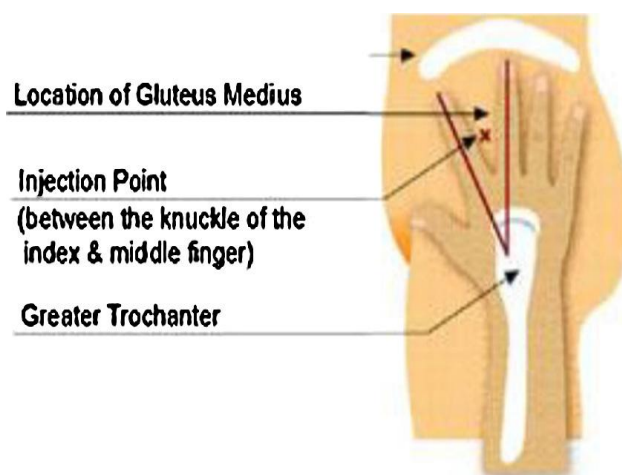
In the literature, these are stated that the muscles in ventrogluteal site are well developed in adults and children, it can be used in children after seven months, it is also a suitable site for intense and irritating drugs (Cook and Murtagh, 2006, Gray and Miller, 2008, Tuğrul and Denat, 2014). However, whereas, if there is any complications developed at the injection site and the children have not reach seven month, it also highlighted ventrogluteal site should not be used for injection (Carter and Mccoy,

2008, Cocoman and Murray, 2008). In the literature; ventrogluteal site can be easily applied when the patient in lying supine, prone or side-lying position, it is easier to position the patient when using this injection site (Hemsworth, 2000, Potter and Perry, 2005, Zimmermann, 2007). Nevertheless, it is reported that this injection site can be used on thin and mildly obese patients, but the length of the needle should be greater for obese individuals (Carter and Mccoy, 2008, Cocoman and Murray, 2008). In the studies, it has been stated that in an intramuscular injection practice which made with 21 gauge needle, in terms of achieving the needle into the muscle tissue, the ventrogluteal site is specified reliable than dorsogluteal site (Diegle and Deeks, 2000; Nisbet, 2006).

Ventrogluteal site is considered as the most reliable and least painful site for the injection applications. The reason for this; there is no large blood vessels or nerves and it is far from the bone tissue in ventrogluteal site (Beecroft and Redick 1990, Donaldson and Green, 2005, Nicoll and Hesby, 2002). Covington and Trattler (2007) in their study, they stated that the ventrogluteal site is the safest and least painful site for intramuscular injections. Moharreri et al. (2007) in their study, it is recommended to select ventrogluteal site for intramuscular injection because of it causes less pain and bleeding than dorsogluteal site. In a study that examined the effects of site that used in intramuscular injection applications on pain by Güneş et al. (2013), it was found that the after injections in ventrogluteal site, pain level of patients' were found to be lower than dorsogluteal site's usage.

### **The Studies Focused on Review The Reliability of The Detection of Ventrogluteal Site**

Today, there is two method are used in detection of ventrogluteal site that "V method" and "G method" (Kaya et al., 2015). In "V method's usage, if nurse use patient's left side hip, uses her right hand, if nurse use right side hip she puts his left hand on great trochanter of femur. Nurse moves her thumb to crotch of patient. Nurse puts her index finger to the anterior superior iliac crest, by open her middle finger to posterior superior iliac crest, she creates a "V" site. Injection site is the midpoint of this "V" site (Figure 1) (Cook and Murtagh, 2006, Güneş et al., 2008, Kilic et al., 2014). However, it is stated that this method was not adopted in many nurses, because of the differences in the nurse's hand structure and patient's body structure this method is not practical (Güneş et al., 2008).



**Figure 1. Determination according to the V method of intramuscular injection site in ventrogluteal site.**

(Reference; Kaya et al. *The reliability of site determination methods in ventrogluteal area injection: a cross-sectional study. International Journal of Nursing Studies, 2015; 52: 355–360*).

Güneş et al (2008) in a study conducted in order to examine the reliability of the detection method; it was stated that this method is reliable on body mass index of all the individuals between 18.5-29.9 (100%), 15% of individuals between 30-39.9, and all of the individuals who are 40 or over, this method is not reliable. Also in this study; it is indicated that the reliability of the method used decrease in particularly obese individuals. In method of detecting the ventrogluteal site by using “Geometric methods (G method)”, by referencing the bone prominences, and imaginary lines are drawn in between the bone ends. With this, an imaginary line is drawn from the greater trochanter to the iliac crest of the iliac tubercule, then to the anterosuperior iliac spine, and from the greater trochanter to the anterosuperior iliac spine. Thus, a triangle is created by imaginary lines. After that, median lines are drawn for every single corner of triangle. As shown in Fig. 2, the convergence point of the three median lines is the barycenter for the triangle. In other words, this barycenter is the needle entry point for intramuscular injections (Meneses, 2007; Kaya et al., 2015). In a study carried out by Meneses (2007), it is found that G method is 100% reliable in determination of the ventrogluteal site in intramuscular injections. In a study conducted to examine the reliability of the two different methods that “V method” and “G method” which are used in determine the ventrogluteal site by Kaya et al (2015), it is found that in the site where used the G method, the thickness of subcutaneous tissue less than the site defined by the V method, and the thickness of gluteus minimus muscle has been

found larger. Thus, in the light of results of the study; G method is determined as a reliable method for determination of ventrogluteal site.

#### **Reasons of Not Preference of The Ventrogluteal Site in Practices**

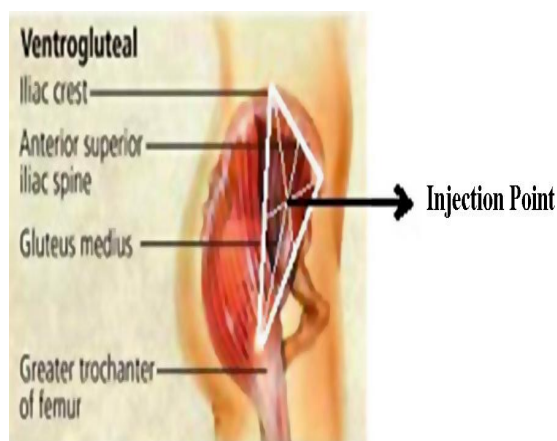
In the literature, it is stated that the health professionals’ knowledge and skills in the use of ventrogluteal site are not adequate and therefore, they are reluctant to give injections in this site. (Greenway, 2004, Nioll and Hesby, 2002). Floyd and Meyer (2007), stated that in some nursing schools, injection techniques on ventrogluteal site has been taught, but students rarely observed this technique in practice.

In light of the studies, when it is examined that the reasons to not use this site in practice; it is shown that they believe ventrogluteal site is not secure as dorsogluteal site and difficulties in experiences of determination of the site. In addition, if the injection have done in this site, a vast majority of health professionals think they can harm the patients (Cook and Murtagh, 2006, Donaldson and Green, 2005, Greenway, 2004).

Wyaden et al. (2006) in their study; they stated that nurses do not use the ventrogluteal site constantly, they are extremely resistant to change and it is very difficult to give up this habit for them. Nurses in this study, as justification for their not use in this site, they stated that the ventrogluteal site is not secure as dorsogluteal site they think, it is difficult to identify this site anatomically and injection between the

forefinger and middle finger is hard to apply. Alannah and Floyd (2007), in their study, as the reason for nurses do not use this injection site; they stated that it is difficult to identify this site, the evidences on this issue is not enough to change nurses' practice, nurses slog to change their accustomed method with another method. In the

study carried out by Tuğrul and Denat (2014), it is indicated that most of the nurses have insufficient information about ventrogluteal site, they found this area safe, but they are accustomed for other injection site and for this reason they not prefer to use ventrogluteal site.



**Figure 2. Determination according to the G method of intramuscular injection site**

(Reference; Kaya et al. *The reliability of site determination methods in ventrogluteal area injection: a cross-sectional study. International Journal of Nursing Studies, 2015; 52: 355–360*).

## Conclusion

In the light of literature and studies, as a result of this compilation we made; it is risky that using dorsogluteal site in intramuscular injection practices, using ventrogluteal site have many advantages and for this reason it was concluded that using ventrogluteal site should not be defined as an alternative, it should be defined as a priority site for intramuscular injection practices. Furthermore, although the ventrogluteal site is defined as the safe injection site, it was seen that most of health professionals in many applications, they not prefer the ventrogluteal site. Based on these results;

- To teach the intramuscular injection practice into the ventrogluteal site as applied within scope of the in-service training for health professionals and regulation of interval training program to make it practicable,
- To share the results of studies conducted on the use of ventrogluteal site in intramuscular injections,
- To do more studies regarding to the reliability of detection method of ventrogluteal site,

- It is recommended to emphasize to especially nursing students, health profesionelns, students and clinical practitioners that it should be considered as a first option which choosing ventrogluteal site as not an alternative to dorsogluteal site.

## Declaration of Conflicting Interests

The author(s) declared no potential conflicts of interest with respect to the paper, authorship, and/or publication of this article.

## Funding

The author(s) received no financial support for the paper, authorship, and/or publication of this article.

## References

- Alannah, M, Floyd S. (2007). Intramuscular injections - what's best practice? Why is there such a gap between what is taught in nursing schools about the best sites end technique for intramuscular injections and what actually happens in practice? Two nurses decided to find out. Kai Tiaki: Nursing New Zealand, 7 (1), 25-31.
- Beecroft P.C., Redick S.A. (1990). Clarification of ventrogluteal site. *Pediatr Nurs*, 16, 396.
- Beyea S.C, Nicholl L.H. (1995). Administration of medications via the intramuscular route: an integrative

- review of the literature and research-based protocol for the procedure. *Applied Nursing Research*, 8 (1), 23-33.
- Berman A, Snyder S. J, Kozier B, Erb, G. (2008). *Kozier & Erb's Fundamentals of Nursing Concepts, Process, and Practice*. 8th ed., Pearson Education Inc., Upper Saddle River, New Jersey, 873-874.
- Carter H, McCoy T.T. (2008). Are we on the same page?: A comparison of intramuscular Injection explanations in nursing fundamental texts. *Medsurg Nursing*, 4 (17), 237-240.
- Chan V.O., Colville J, Persaud T, Buckley O, Hamilton S, Torreggiani W.C. (2006). Intramuscular injections into the buttocks: Are they truly intramuscular?. *European Journal Of Radiology*, 58, 480- 484.
- Chung J.W.Y., Wong T.K.S. (2002). An experimental study on the use of manual pressure to reduce pain in intramuscular injections. *Journal Of Clinical Nursing*, 11, 457- 461.
- Cocoman A, Murray, J. (2008). Intramuscular injections: A review of best practice for mental health nurses. *Journal of Psychiatric and Mental Health Nursing*, 15, 424- 434.
- Cocoman A, Murray J. (2010). Recognizing the evidence and changing practice on injection site. *British Journal of Nursing*, 19 (18), 1170-1174.
- Cook I.F., Murtagh J. (2006). Ventrogluteal area – A suitable site for intramuscular vaccination of infants and toddlers. *Vaccine*, 24, 2403-2408.
- Covington T.P., Trattler M.R. (1997). Bull's-eye! Finding the right target for i.m. injections. *Nursing*, 27 (1), 62-63.
- Craven R. F., Hirnle C. J. (2000). *Fundamentals of Nursing Human Health and Function*. 3rd ed., Lippincott Williams & Wilkins, Philadelphia.
- DeLaune S.C., Ladner P.K. (2002). *Fundamentals of Nursing: Standards and Practice*. Clifton Park, New York: Thomson Delmar Learning, 713-716.
- Diggle L, Deeks J. (2000). Effect of needle length on incidence of local reactions to routine immunisation in infants aged 4 months: randomised controlled trial. *British Medical Journal*, 14, 931–933.
- Donaldson C, Green J. (2005). Using the ventrogluteal site for intramuscular injection. *Nursing Times*, 101 (16), 36-38.
- Elizabeth H, Winslow R.N. (1996). The right site for i.m. injections. *American Journal of Nursing*, 96(4), 53.
- Engstrom J.L, Giglio N.N, Takacs S.M, Ellis M.C, Cherwenka D.I. (2000). Procedures used to prepare and administer intramuscular injections: a study of infertility nurses. *Journal of Obstetric Gynecologic and Neonatal Nursing*, 29 (2): 159-168.
- Floyd S, Meyer A. (2007). Intramuscular injections –what's best practice? *Nursing New Zealand*, 13 (6), 20-22.
- Gray T, Miller H. (2008). Injection technique. *The Foundation Years*, 6 (4), 252- 255
- Greenway K. (2004). Using the ventrogluteal site for intramuscular injection. *Nursing Standard*, 18 (25), 39-42.
- Greenway K. (2014). Rituals in nursing: intramuscular injections. *Journal of Clinical Nursing*, 23, 3583-3588.
- Gülner E, Çalışkan N. (2014). Ventrogluteal intramuscular injection for Nurse Examination of knowledge for practice. *DEUHYO*, 7 (2), 70-77.
- Güneş Ü. Y., Zaybak A, Tamsel S. (2008). Examining the reliability of the method used for the determination of ventrogluteal. *Cumhuriyet University School of Nursing Journal*, 12 (2), 1-8.
- Güneş Ü.Y., Zaybak A, Biçici B, Çevik K. (2009). Nurses Examination of application intramuscular injection process. *Journal of Ataturk University School of Nursing*. 12 (4), 84-90.
- Güneş Ü.Y., Kara D, Arı S, Ceyhan O. (2013). Which site is more painful in intramuscular injections? The dorsogluteal site or the ventrogluteal site? A case study from Turkey. *Clinical Nursing Studies*, 1 (4), 74-81.
- Hemsworth S. (2000). Intramuscular (IM) injection technique. *Pediatric Nursing*, 12 (9), 17- 20.
- Hogston R, Simpson P.M. (2002). *Foundations of Nursing Practice: Making the Difference*. 2nd Edition. Basingstoke, Hampshire: Polgrave.
- Hunter J. (2008). Intramuscular injection techniques. *Nursing Standard*, 22 (24), 35- 40.
- Kaya N, Salmaslıoğlu A, Terzi B, Turan N, Acunaş B. (2015). The reliability of site determination methods in ventrogluteal area injection: A cross-sectional study. *International Journal of Nursing Studies*, 52, 355-360.
- Kilic E, Kalay R, Kilic C. (2014). Comparing applications of intramuscular injections to dorsogluteal or ventrogluteal regions. *Journal of Experimental and Integrative Medicine*, 4 (3), 171-174.
- Kozier B, Berman A (2008). *Fundamentals of Nursing: Concepts, Process, and Practice*. 8th Edition. Pearson Prentice Hall, Upper Saddle River, NJ.
- Malkin B. (2008) Are techniques used for intramuscular injection based on research evidence?, *Nursing Times*, 104, 48-51.
- Meneses, A.S. (2007). A proposal for a geometrical delimitation model for ventro-gluteal injection. *Rev. Bras. Enferm*, 60, 552–558.
- Moharreri A.R, Nasiri H, Jahanshahi M, Rahmani H, Abdollahi A, Rabiei M. (2007). The comparison of pain intensity and rate of bleeding in intramuscular injection in dorsogluteal and ventrogluteal area. *Journal of Gorgan University of Medical Sciences*, 9 (3), 37-41.
- Newton M, Newton D.W, Fudin J. (1992). Reviewing the “big three” injection routes. *Nursing*, 22 (2): 34-42.
- Nicoll L.H., Hesby A.(2002). Intramuscular injection: an integrative research review and guideline for evidence-based practice. *Applied Nursing Research*, 15 (3), 149-62.
- Nisbet, A.C. (2006). Intramuscular gluteal injections in the increasingly obese population: retrospective study. *BMJ*, 332, 637-638.
- Pandian J.D., Bose S, Daniel V, Singh Y, Abraham A.P. (2006). Nerve injures following intramuscular injections: a clinical and neurophysiological study from northwest India. *Journal of the Peripheral Nervous System*, 11:165–171.
- Potter P.A., Perry A.G. (2005). *Fundamentals of Nursing*, 6th. Ed., Philadelphia: Louis Mosby.
- Ramont R.P, Niedringhaus D.M. (2004). *Fundamental Nursing Care*. 6th Edition. Pearson Prentice Hall, Upper Saddle River NJ
- Ramtahal J, Ramlakhan S, Singh K. (2006). Sciatic nerve injury following intramuscular injection: a case report and review of the literature. *The Journal of Neuroscience Nursing*, 38 (4), 238-240.

- Rodger M.A., King L.(2000). Drawing up and administering intramuscular injections: a review of the literature. *Journal of Advanced Nursing*, 31 (3), 574- 582.
- Small P.S. (2004). Preventing sciatic nerve injury from intramuscular injections: literature review. *Journal of Advanced Nursing*, 47 (3), 287-296.
- Soanes N. (2000). Injection site safety. *Nursing Standard*, 14, 55.
- Stringer M.D., Mishra P. (2010). Sciatic nerve injury from intramuscular injection: a persistent and global problem. *Clin Pract*, 64 (11), 1573–1579.
- Taylor C, Lillis C, LeMone P, Lynn P. (2008). *Fundamentals of Nursing The Art And Science of Nursing Care*. 6th ed., Wolters Kluwer Lippincott Williams & Wilkins, Philadelphia.
- Tuğrul E, Denat Y. (2014). Nurses ventrogluteal field injection practices related to knowledge, opinions and practices. *DEUHYO*, 7 (4), 275-284.
- Walsh L, Brophy K. (2011). Staff nurses' sites of choice for administering intramuscular injections to adult patients in the acute care setting. *Journal of Advanced Nursing*, 67 (5), 1034-1040.
- Workman B. (1999). Safe injection techniques. *Nursing Standard*, 13, 47-53.
- Wyaden D, Landsborough I, McGowan S, Baigmohamad Z, Finn M, Pennebaker, D. (2006). Best practise guidelines for the administration of intramuscular injections in the mental health setting. *International Journal Of Mental Health Nursing*, 15, 195-200.
- Yavuz E.D, Karabacak Ü. (2011). İntramüsküler enjeksiyonda neden ventrogluteal bölgeyi tercih etmeliyiz? *Hemşirelikte Araştırma Geliştirme Dergisi*, 2: 81-88.
- Zaybak A, Güneş Ü.Y., Tamsel S, Khorshid L, Eşer İ. (2007). Does obesity prevent the needle from reaching muscle in intramuscular injections? *Journal of Advanced Nursing*, 58 (6), 552-556.
- Zimmermann G.P. (2010). Revisiting IM injections; the ventrogluteal site is the safest for intramuscular injections. *The American Journal of Nursing*, 110 (2), 60-61.